

A Review on Thrombosis and Its Possible Treatments

C. JYOTHI¹, K. MAHESHWARI², SHILAMKOTI GEETHA³, K. SRAVANTHI GOUD⁴, J.V.C SHARMA⁵

^{1, 3, 4} Student of Joginpally B.R Pharmacy College, Bhaskar Nagar, Yenkapally, Moinabad, Telangana, India

² Department of Pharmaceutics, Faculty of Pharmacy, Joginpally B.R Pharmacy College, Bhaskar Nagar, Yenkapally, Moinabad, Telangana, India

⁵ Department of Pharmacognosy, Faculty of Pharmacy, Joginpally B.R Pharmacy College, Bhaskar Nagar, Yenkapally, Moinabad, Telangana, India

Abstract- Thrombosis – Localized clotting of the blood can occur in the arterial or the venous circulation and has major medical impact. Acute arterial thrombosis is the proximal cause of most cases of myocardial infarction (heart attacks) and about 80% of strokes, collectively the most common cause of death in the developed world. Venous thrombosis is the leading cause of cardiovascular associated death. The pathologic changes that occur in the blood vessel result in thrombosis. Present review is about the thrombosis & its types, various methods of treatments, devices, complications & its statistical analysis, thrombosis treatments for its safe & cost-effective treatments.

Indexed Terms- Arterial thrombosis, Thrombosis, Treatments, Venous thrombosis.

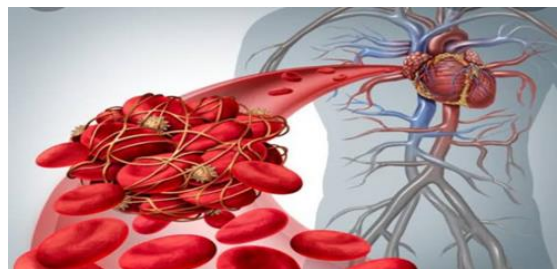I. INTRODUCTION

Thrombosis is a blood clot within blood vessels that limits the flow of blood. Acute venous and arterial thrombosis is the most common cause of death in developed countries. It prevents the blood from flowing normally through circulatory system.[1]

Coagulation, or blood clotting, is the body's first line of defense against bleeding. The clotting system in the human body guards against blood loss. Our clotting system generates a "Plug" or "Seal" to protect us from losing too much blood when we have a heart attack. [2]

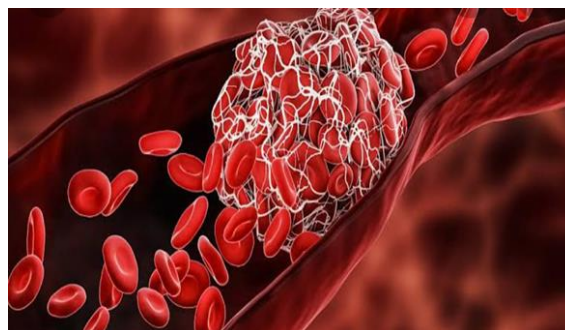
After we've heard, our bodies break down the clot; however clots can form spontaneously or fail to

disintegrate after an injury. A blood clot that forms and stays in a blood vessel is called a thrombus.



II. THROMBOSIS

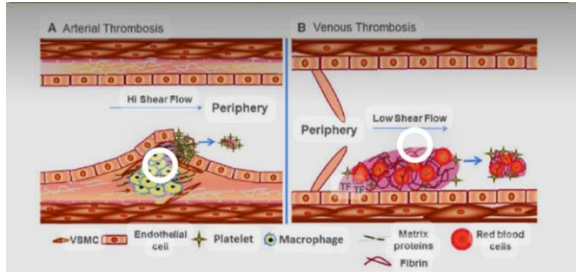
Thrombosis is the formation of a blood clot (partial or total blockage) in thin blood arteries, either venous or arterial, which prevents the natural flow of blood and causes clinical sequelae. Blood flow in vessels is dependent on a complex homeostasis involving blood cells (including platelets), plasma proteins, coagulation factors, inflammatory endothelial lining of arteries and veins, and growth factors and cytokines. When this physiologic mechanism is disrupted, the likelihood of having a thrombosis rather than a coagulopathy increases (Increased risk of bleeding). (1)



III. TYPES OF THROMBOSIS

There are mainly two types of thrombosis.

1. venous thrombosis
2. Arterial thrombosis



IV. VENOUS THROMBOSIS

Venous thrombosis is when the blood clot blocks a vein. Veins carry blood from the body back into the heart.

Venous thromboembolism management encompasses the use of various anticoagulant agents that have the largest procoagulant factors. Whereas arterial thrombosis management is predominantly with antiplatelet agents as monotherapy or dual-antiplatelet therapy. [3]

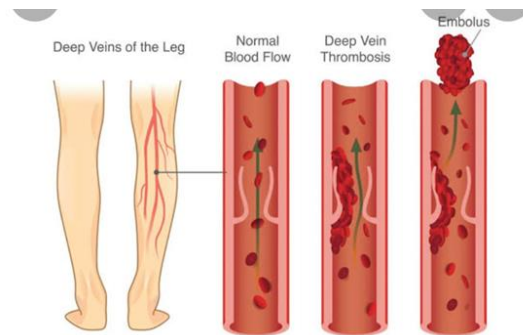
V. THESE ARE TWO SUBTYPES

- 1) Deep-vein thrombosis (DVT)
- 2) Pulmonary embolism (PE)

VI. DEEP -VEIN THROMBOSIS

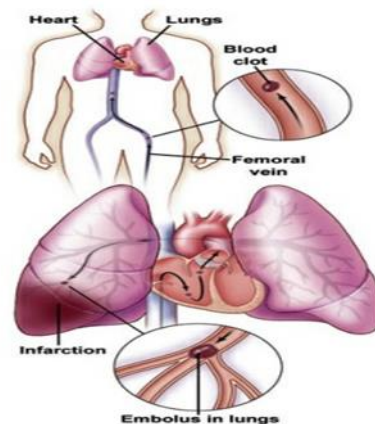
DVT is most commonly found in the calf portion of the leg. The majority of thrombi originate in the deep veins below the popliteal trifurcation (distal DVT), which are most likely to dissolve spontaneously without causing any symptoms. Deep-vein thrombosis forms when there is clot in arm, leg or pelvis. PE occurs when part of DVT breaks off and travels through blood stream to the lungs, causing a blockage in the blood vessel of the lungs.[4] Deep-vein thromboses (DVT) is a common and serious condition. It's a symptom of venous thromboembolism, which is the third leading cause of death from cardiovascular illness after heart attacks and stroke.[5] Venous thrombosis occurs in regions where blood flow is reduced or physically

altered, such as the pockets close to valves in the leg's deep veins.[6]

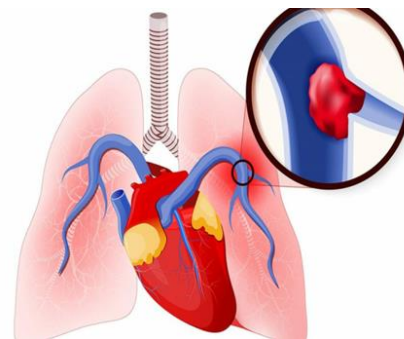


VII. PULMONARY EMBOLISM

When clots break off and embolize into the pulmonary circulation, this is known as pulmonary embolism. (7)

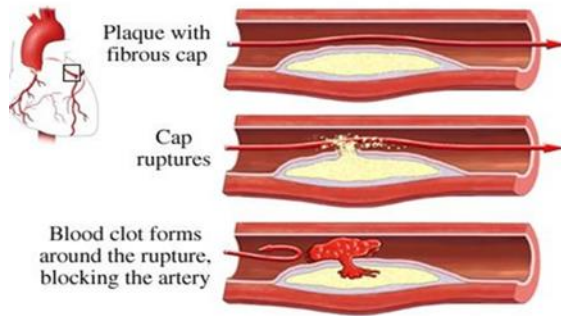


A thrombus that originates elsewhere disrupts the flow of blood in the pulmonary artery or its branches, resulting in pulmonary embolism (PE). A thrombus develops within the deep veins of the lower limbs in deep vein thrombosis (DVT).[8]

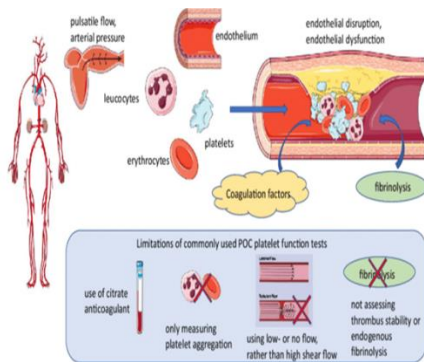


VIII. ARTERIAL THROMBOSIS

Arterial thrombosis usually develops after the erosion or rupture of an atherosclerotic plaque and can result in ischemic damage, especially in tissues with a terminal vascular bed, due to platelet-mediated thrombosis.[9]



This involves thrombus developing in an artery. Arteries are blood vessels that carry oxygenated blood away from the heart to other areas of the body, cases of arterial thrombosis may be minor or severe depending on the size of thrombosis and the artery in which it develops. Antithrombin, protein C, and protein S deficits are rare but significant risk factors for venous thrombosis; however, they have little or no influence on arterial thrombosis.[10]



IX. TYPES OF TREATMENT

The most common and effective treatments for thrombosis are medications called anticoagulants that help prevent the formation of new-blood clots. Usually, a person receives injectable anticoagulants such as heparin or low- molecular weight heparin.

These medications begin working within hours. A person with thrombosis may be given tissue plasminogen activators in an emergency circumstance. They promote the production of the enzyme plasmin, which is involved in dissolving clots.

X. ANTICOAGULATION

Warfarin and vitamin K antagonists can be taken orally to reduce thromboembolic occurrence for more effective reprise heparin may be given. Most patients who needed parenteral anticoagulation were given heparin, whereas those who needed oral anticoagulation were given warfarin.[11]

Long-term anticoagulation following a thrombotic incident or avoidance of thrombotic occurrences in individuals at high risk, including post-operative states, atrial fibrillation, and those with artificial valves, are among the reasons for warfarin.[11]

XI. THROMBOLYSIS

Thrombolytic treatment, also known as fibrinolytic or thrombolysis, is used to dissolve hazardous intravascular clots and improve blood flow to prevent ischemic damage. This is the pharmacological destruction of blood clots by administering thrombolysis change using RTP activator. [12]

- WHICH ENHANCES THE NORMAL DISCRETION OF BLOOD CLOTS BY THE BODY'S ENZYMES?

This carries an increased risk of bleeding generally not used in spec ITive situations (such as severe stroke or massive pulmonary embolism).

The mainstay of thrombolysis in acute ischemic stroke is intravenous alteplase (tPA), which improves functional outcomes significantly when given within 4.5 hours of the beginning of the stroke.[13]

XII. SURGICAL THROMBECTOMY

Pulmonary embolism has a wide range of treatments, many of which are complicated. Current evidence on surgical thrombectomy is crucial, although it is difficult to come by. We used the National Inpatient

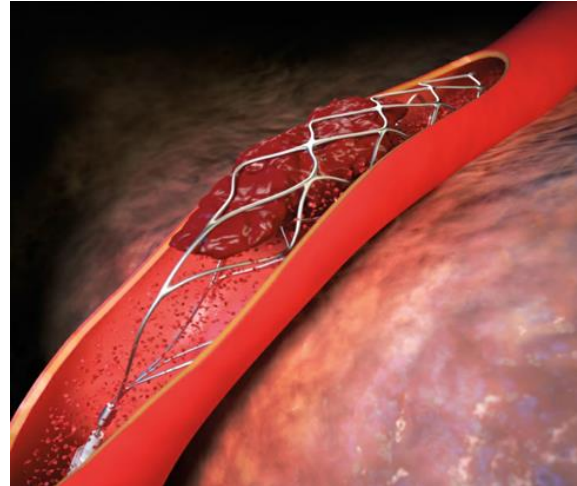
Sample to look at trends in surgical thrombectomy performance rates and outcomes in the United States from 2003 to 2014 [14] The widely used national data comes from older studies; in one, surgical thrombectomy is linked to a 27.2 percent perioperative death rate.[15]

XIII. ENDOVASCULAR TREATMENT

Mechanical clot retrievals and catheter guided thrombolysis are used in certain situations.

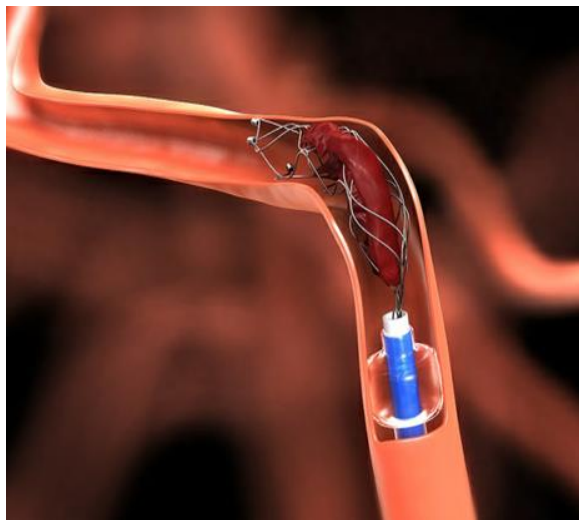
XIV. STENT RETRIEVER

Stent retrievers have the potential to be identified as the most important method for treating endovascular stroke.[16]The "stent retrievers" appear to be the most promising endovascular mechanical therapy device in terms of reducing the time to recanalization and achieving a higher rate of total clot resolution with more feasibility.[17]Mechanical thrombectomy using stent retrievers appears to be a potential therapy option for AIS.The safety and effectiveness of Stent Retrievers in animal models gave significant technical data with clinical inferences.[18]



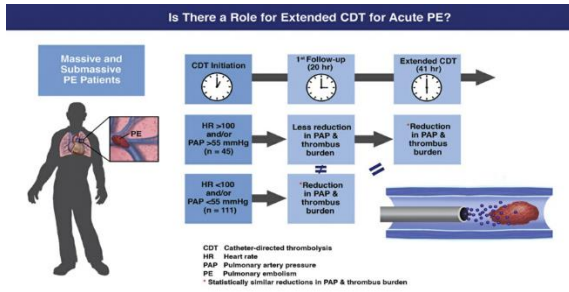
Many single-center trials using stent retrievers have demonstrated the ability to reduce procedure time (42-55 minutes) and enhance recanalization rates in big cerebral arteries by more than 80 to 90%, with good clinical outcomes in a large percentage of patients (42-54 percent). [19-21] The average proportion of death in patients treated with stent retrievers was 21.4 9.4% in a case series (n = 1,168). [22-29]

XV. CATHETER



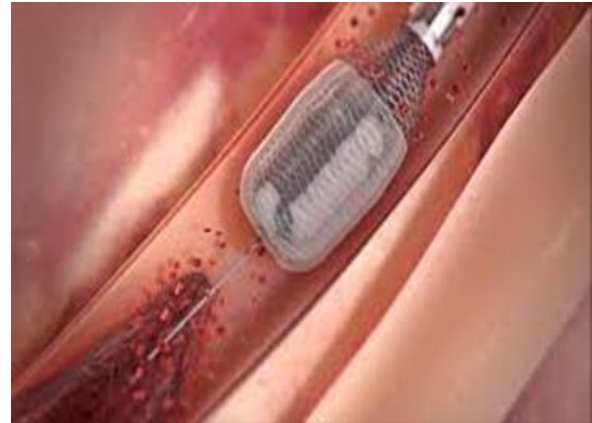
CDT (catheter-directed thrombolysis) is a minimally invasive endovascular treatment used in conjunction with anticoagulation. By lowering clot burden and protecting against valvular damage, CDT reduces the incidence of PTS. Under fluoroscopy, a catheter is inserted straight to the thrombosis site, followed by a slow, protracted infusion of a low-dose thrombolytic drug.CDT entails the percutaneous insertion of a catheter into the venous system, followed by fluoroscopic guiding to the target vessel and the continuous infusion of a thrombolytic drug such as tPA into the thrombus. The catheter is normally left in place for at least 24 hours, and the infusion continues.[30]

Follow-up venograms are taken every 8 to 24 hours to check for any remaining thrombus and, if necessary, adjust the catheter.[31]

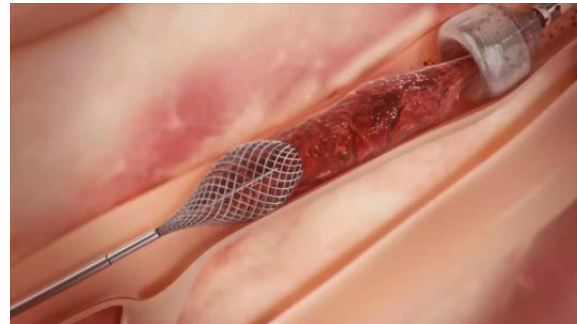
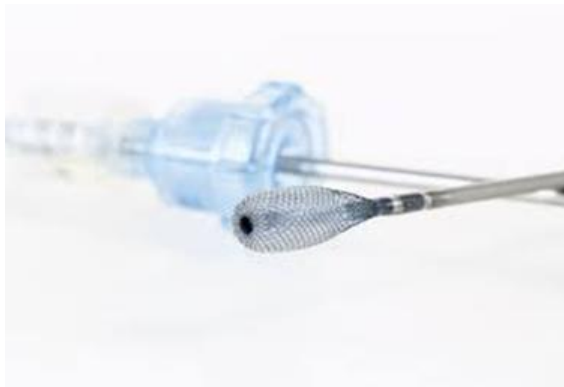
XVI. MEGAVAC SYSTEM

The Megavac Thrombectomy System is a single-use intravascular mechanical thrombectomy and aspiration system that includes an embolectomy element on the ThromboWire.



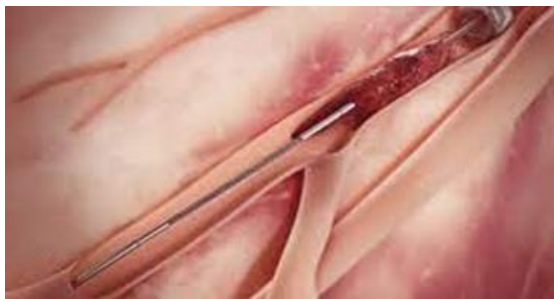STEP-2: The stent retriever is put through the micro-catheter and then the clot after the micro-guidewire is removed.



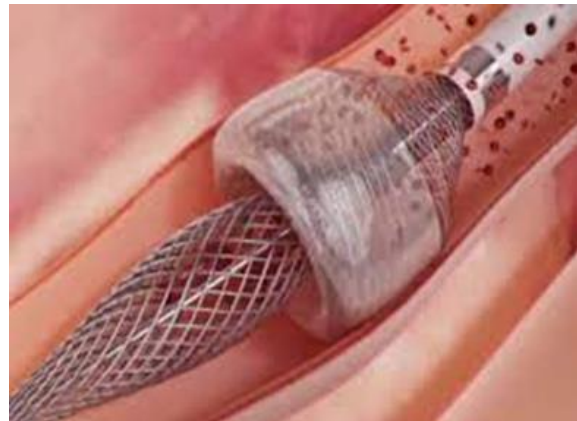
STEP-3: The stent retriever is opened like a stent and deployed into the clot directly.

XVII. MEGAVAC TREATMENT

Megavac is used for the treatment of thrombosis in the following ways [32].



STEP-1: The interventional radiologist will insert a size 8Fr catheter into the internal carotid artery through femoral arterial puncture once a GA or acceptable doses of sedation have been attained. Intermediate-sized catheters are inserted into the 8Fr catheter and guided to the Willis circle.



STEP-4: As the clot is pushed back into the intermediate catheter with the retriever, suction is applied. To avoid distal embolisation during stent retrieval into the guide catheter, proximal balloon

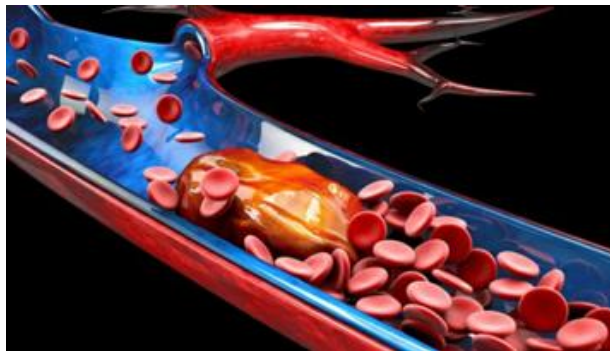blockage and flow reversal by added aspiration at the guide catheter is indicated.

XVIII. ANTIPLATELET

Aspirin may be used to reduce the risk of recurrence or progression. Antiplatelet medicines are pharmaceuticals that are often used to prevent thrombus development by reducing platelet aggregation. Antiplatelet medicines, according to clinical and experimental evidence, can reduce the onset and spread of venous thrombus, reducing the risk of PE and DVT (Castro 2006).[33]

XIX. MECHANICAL THROMBECTOMY / TREATMENT

Endovascular technique for removing blood clots from the brain after an ischemic stroke. More attention to the need for shorter time to imaging and treatment, more accurate imaging to document large vessel occlusion, and technological improvements resulting in second generation stenting devices, which may achieve complete or near-complete recanalization in 70–85 percent of patients compared to 40–50 percent for first generation stenting devices, are some of the reasons for better outcomes in recent RCTs on mechanical thrombectomy. According to the DEFUSE3 trial (Albers et al., 2018a) and the DAWN trial (Albers et al., 2018b), the time window for mechanical thrombectomy may be further extended in selected subpopulations of patients, up to 16 hours in the DEFUSE3 trial and up to 24 hours in the DAWN trial (Nogueira et al., 2018).[34]



In the population with a high thrombus burden, mechanical thrombectomy outperforms manual

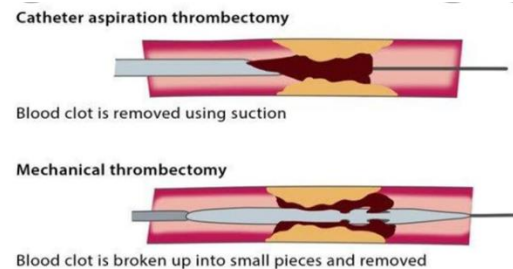
thrombectomy in terms of preventing re-MI and stroke.[35]

XX. ISCHEMIC STROKE

This stroke is a more common type. It is usually caused by a blood clot that blocks a blood vessel in the brain, this keeps blood from flowing to the brain within minutes brain cells have to die. Patients with large vessel ischemic stroke and good CT perfusion were randomized to either endovascular thrombectomy after alteplase or alteplase alone. The 90-day modified Rankin scale was used to assess clinical outcome (mRS).[36]

XXI. TREATMENT OF MT

MT is a type of minimally invasive procedure in which an interventional radiologist uses specialized equipment to remove the clot from patient's artery using fluoroscopy or continuous X-ray, c the doctor guides instruments through the patient's arteries to the clots extracting the clot all at once.



XXII. WHEN TO DO MT 9

It is indicated for patients with acute ischemic stroke due to a large artery occlusion in the anterior circulation. Who can be treated within 24 hours of the last known to be well (at neurologic baseline)

XXIII. ADVANTAGES OF THE TREATMENT OF THROMBECTOMY

- Improved mobility and quality of life post treatment.
- Procedure itself is relatively simple.
- Recovery rate is fairly quick.

- Surgical site is a small incision in the upper thigh and provides surgeons with a far less invasive way of accessing the clot location.
- Ideally not is peymal within 6 hours of ischemic stroke.
- There may even be noticeable improvement in medicatiately upon removal of the thrombus and restriction of blood flow.
- Surgical recovery is generally quick and straightforward.
- Mechanical thrombectomy is a promising alternative to traditional stroke therapies. By MT device we can get good angiographic results and clinical outcomes.

XXIV.COMPLICATIONS

- Dislodging of embolic material at the occlusion's proximal end.
- Thrombectomy can potentially result in thrombectomy-related stenosis at the thrombectomy site.
- Vessel perforation and dissection are possible complications.
- Hematomas in the groyne and retroperitoneum might develop at the puncture site.
- Reocclusion due to a high platelet count on admission, stenosis, or embolic debris near the thrombectomy site.[37]

XXV. STATISTICS

The total number of thrombectomy eligible patients could range from 10 to 20 patients every 100000 person years, depending on the success rate of the procedure.[38]

Among 323 AIS patients rated with mechanical thrombectomy the overall rate of successful recanalization was 86% and the overall post procedure mortality rate was 29% by 90 days.[39]

After analysis a baseline multivariable model comprised of history of stroke (OR 0.28, 95% CI 0.69-0.68) pre-shore modified rankin scale (MRS 2 OR 3.75, 95%CI) several admission national institutes of health stroke scale (NII + SS21-42: OR 12.36, 95% C1 1.48-103.27), internal carotid artery (ICA) occlusion (

Or 2.69, 95% C1 !.06-6.83) was prognostic of 90 day mortal.[40]

CONCLUSION

MT's cost-effectiveness has been studied all throughout the world. MT with and without IVT compared to standard cases is cost-effective over extended time horizons due to increased survival and quality of life and decreased long-term care. (ie., nursing and rehabilitation facilities).

The majority of AIS economic studies originate from industrialized countries, but they are growing into new locations, and expenses can be differentiated by age, surgery type, and baseline patient status.

India has transgressed through significant demographic, economic, and epidemiological changes, resulting in increased life expectancy and a growing aging population. In fact, during the past two decades the cumulative incidence (105 to 152/100000 persons per year) and crude prevalence (44.29 to 559/100000) of stroke ranged greatly across different parts of the country. In comparison to global estimates, this stroke incidence and prevalence rates are higher than those of high-income countries. A2014 retrospective study analyzed patient outcomes for endovascular treatment of AIS with LVO stroke in an Indian tertiary care center. All patients had contraindications to or failed intravenous thrombolysis prior to endovascular treatment. Forty-five patients were included with a mean age of 49+-14 years and 71% (32/45) were male. At 90-day follow-up 64% of patients had good outcomes, while 36% had poor outcomes: half of these died.

REFERENCES

- [1] Damilola Ashorobi1; Muhammad Atif Ameer2; RobertoFernandez3., Thrombosis, Book, Last Update: September 9, 2021.
- [2] Cyrus Garmo1; Tanvir Bajwa2; Bracken Burns3., Physiology, Clotting Mechanism. Books, Last Update: September 8, 2021.
- [3] Alisa S Wolberg,Frits R Rosendaal,Jeffrey I Weitz,Iqbal H Jaffer,Giancarlo Agnelli,Trevor

- Baglin, Nigel Mackman., Venous thrombosis, Nat Rev Dis Primers. 2015 May 7; 1:15006.
- [4] Fatemeh Moheimani and Denise E. Jackson., Venous Thromboembolism: Classification, Risk Factors, Diagnosis, and Management, ISRN Hematol. 2011; 2011: 124610.
- [5] Sheikh M. Waheed¹; Pujitha Kudravalli; David T. Hotwagner²., Deep Vein Thrombosis, Books, Last Update: August 11, 2021.
- [6] Nicolaides AN, Kakkar VV, Field ES, et al. The origin of deep vein thrombosis: a venographic study. *Br J Radiol* 1971; 44:653-63. 10.1259/0007-1285-44-525-653
- [7] Moser KM. Venous thromboembolism. *Am Rev Respir Dis*. 1990 Jan; 141(1):235-49.
- [8] COON WW, WILLIS PW. Deep venous thrombosis and pulmonary embolism: prediction, prevention and treatment. *Am J Cardiol*. 1959 Nov; 4:611-21.
- [9] Emanuele Previtali, Paolo Bucciarelli, Serena M. Passamonti, Ida Martinelli., Risk factors for venous and arterial thrombosis, *Blood Transfus*. 2011 Apr; 9(2): 120–138.
- [10] Seligsohn U, Lubetsky A. Genetic susceptibility to venous thrombosis. *N Engl J Med*. 2001; 344:1222–31.
- [11] Katherine Harter, MD, Michael Levine, MD, and Sean O. Henderson, MD., Anticoagulation Drug Therapy: A Review, *West J Emerg Med*. 2015 Jan; 16(1): 11–17.
- [12] Muhammad U. Baig¹; Jeffrey Bodle²., Thrombolytic Therapy, Books, Last Update: June 17, 2021.
- [13] Dillon GM, Stevens S, Dusenbury WL, Massaro L, Toy F, Purdon B. Choosing the Correct "-ase" in Acute Ischemic Stroke: Alteplase, Tenecteplase, and Reteplase. *Adv Emerg Nurs J*. 2019 Jul/Sep; 41(3):271-278.
- [14] Fahad Alqahtani, MD, Muhammad Bilal Munir, MD, Sami Aljohani, MD, Abdul Tarabishy, MD, Ahmad Almustafa, MD., Surgical Thrombectomy for Pulmonary Embolism: Updated Performance Rates and Outcomes, *Tex Heart Inst J*. 2019 Jun; 46(3): 172–174.
- [15] Kilic A, Shah AS, Conte JV, Yuh DD. Nationwide outcomes of surgical embolectomy for acute pulmonary embolism. *J Thorac Cardiovasc Surg*. 2013; 145(2):373–7.
- [16] Paramdeep Singh, Rupinderjeet Kaur, and Amarpreet Kaur., Endovascular treatment of acute ischemic stroke, *J Neurosci Rural Pract*. 2013 Jul-Sep; 4(3):298–303.
- [17] Novakovic RL, Toth G, Narayanan S, Zaidat OO. Retrievable stents, “stentriever,” for endovascular acute ischemic stroke therapy. *Neurology*. 2012; 79(13 Suppl 1): S148–57.
- [18] Koh JS, Lee SJ, Ryu CW, Kim HS. Safety and efficacy of mechanical thrombectomy with solitaire stent retrieval for acute ischemic stroke: A systematic review. *Neurointervention*. 2012; 7:1–9.
- [19] Castano C, Dorado L, Guerrero C, Millan M, Gomis M, Perez dIO, et al. Mechanical thrombectomy with the Solitaire AB device in large artery occlusions of the anterior circulation: A pilot study. *Stroke*. 2010; 41:1836–40.
- [20] Roth C, Papanagiotou P, Behnke S, Walter S, Haass A, Becker C, et al. Stent-assisted mechanical recanalisation for treatment of acute intracerebral artery occlusions. *Stroke*. 2010; 41:2559–67.
- [21] Costalat V, Machi P, Lobotesis K, Maldonado I, Vendrell JF, Riquelme C, et al. Rescue, combined, and stand-alone thrombectomy in the management of large vessel occlusion stroke using the solitaire device: A prospective 50-patient single-center study: Timing, safety, and efficacy. *Stroke*. 2011; 42:1929–35.
- [22] Leker RR, Eichel R, Gomori JM, Ramirez de Noriega F, Ben-Hur T, Cohen JE. Stent-based thrombectomy versus intravenous tissue plasminogen activator in patients with acute middle cerebral artery occlusion. *Stroke*. 2012; 43:3389–3391.
- [23] Gratz PP, Jung S, Schroth G, Gralla J, Mordasini P, Hsieh K, Heldner MR, Mattle HP, Mono ML, Fischer U, Arnold M, Zubler C. Outcome of standard and high-risk patients with acute anterior circulation stroke after stent retriever thrombectomy. *Stroke*. 2014; 45:152–158.

- [24] Zaidat OO, Castonguay AC, Gupta R, Sun CH, Martin C, Holloway WE, Mueller-Kronast N, English JD, Linfante I, Dabus G, Malisch TW, Marden FA, Bozorgchami H, Xavier A, Rai AT, Froehler MT, Badruddin A, Nguyen TN, Taqi MA, Abraham MG, Janardhan V, Shaltoni H, Novakovic R, Yoo AJ, Abou-Chebl A, Chen PR, Britz GW, Kaushal R, Nanda A, Issa MA, Nogueira RG, North American Solitaire Stent Retriever Acute Stroke registry post-marketing revascularization and clinical outcome results. *J Neurointerv Surg.* 2014; 6:584–588.
- [25] Pereira VM, Gralla J, Davalos A, Bonafe A, Castano C, Chapot R, Liebeskind DS, Nogueira RG, Arnold M, Sztajzel R, Liebig T, Goyal M, Besselmann M, Moreno A, Schroth G. Prospective, multicenter, single-arm study of mechanical thrombectomy using Solitaire Flow Restoration in acute ischemic stroke. *Stroke.* 2013; 44:2802–2807.
- [26] Yoon W, Jung MY, Jung SH, Park MS, Kim JT, Kang HK. Subarachnoid hemorrhage in a multimodal approach heavily weighted toward mechanical thrombectomy with Solitaire stent in acute stroke. *Stroke.* 2013; 44:414–419.
- [27] Mendonça N, Flores A, Pagola J, Rubiera M, Rodríguez-Luna D, Miquel MA, Cardona P, Quesada H, Mora P, Alvarez-Sabin J, Molina C, Ribo M. Trevo versus Solitaire a head-to-head comparison between two heavy weights of clot retrieval. *J Neuroimaging.* 2014; 24:167–170.
- [28] Jansen O, Macho JM, Killer-Oberpfalzer M, Liebeskind D, Wahlgren N. Neurothrombectomy for the treatment of acute ischemic stroke: results from the TREVO study. *Cerebrovasc Dis.* 2013; 36:218–225.
- [29] San Román L, Obach V, Blasco J, Macho J, Lopez A, Urrea X, Tomasello A, Cervera A, Amaro S, Perandreu J, Branera J, Capurro S, Oleaga L, Chamorro A. Single-center experience of cerebral artery thrombectomy using the TREVO device in 60 patients with acute ischemic stroke. *Stroke.* 2012; 43:1657–1659.
- [30] Drew Fleck, Hassan Albadawi, Fadi Shamoun, Grace Knuttinen, Sailendra Naidu, and Rahmi Oklu. Catheter-directed thrombolysis of deep vein thrombosis: literature review and practice considerations. *Cardiovasc Diagn Ther.* 2017 Dec; 7(Suppl 3): S228–S237.
- [31] Vedantham S, Sista AK, Klein SJ, et al. Quality improvement guidelines for the treatment of lower-extremity deep vein thrombosis with use of endovascular thrombus removal. *J Vasc Interv Radiol* 2014; 25:1317-25. 10.1016/j.jvir.2014.04.019
- [32] Shaun McMahon¹†, Georgina Stocker², Kathryn Bell³., Anaesthetic Management of Endovascular Thrombectomy for Ischaemic Stroke, Anaesthesia tutorial of the week, Published 28 May 2019.
- [33] Carolina DQ Flumignan, Ronald LG Flumignan, and Jose CC Baptista-Silva., Antiplatelet agents for the treatment of deep venous thrombosis, *Cochrane Database Syst Rev.* 2016 Sep; 2016(9): CD012369.
- [34] Cecilia Zivelonghi, MD and Stefano Tamburin, MD, PhD., Mechanical thrombectomy for acute ischemic stroke: the therapeutic window is larger but still “time is brain”, *Funct Neurol.* 2018 Jan-Mar; 33(1): 5–6.
- [35] Eliano Pio Navarese,¹ Giuseppe Tarantini,² Giuseppe Musumeci,³ Massimo Napodano,² Roberta Rossini,³ Mariusz Kowalewski,¹ Anna Szczesniak,¹ Michalina Kołodziejczak,¹ and Jacek Kubica¹. Manual vs mechanical thrombectomy during PCI for STEMI: a comprehensive direct and adjusted indirect meta-analysis of randomized trials, *American journal of cardiovascular diseases,* 2013 Aug 16. Volume 3(3): 146–157.
- [36] Campbell BCV, Mitchell PJ, Churilov L, et al. Endovascular Thrombectomy for ischemic Stroke increases Disability-Free Survival, Quality of Life, and Life Expectancy and Reduces Cost. *Front Neurol.* 2017; 8:657.
- [37] Tawil SE, Muir KW. Thrombolysis and thrombectomy for acute ischaemic stroke. *Clin Med (Lond).* 2017 Apr; 17(2):161-165.
- [38] Ansaar T Rai¹, Aaron E Seldon¹, SoHyun Boo¹, Paul S Link², Jennifer R Domico¹, Abdul R Tarabishy³, <http://orcid.org/0000-0002-7961-3701> Noelle Lucke-Wold¹, Jeffrey S Carpenter¹

- [39] Hannah Lin., Factors Associated with Mortality After Undergoing Thrombectomy for Acute Ischemic Stroke, June 12, 2020.
- [40] Terence J. Quinn,¹ * Martin Taylor-Rowan,¹ Aishah Coyte,¹ Allan B. Clark,² Stanley D. Musgrave,² Anthony K. Metcalf,³ Diana J. Day,⁴ Max O. Bachmann,² Elizabeth A. Warburton,⁴ John F. Potter,^{2,3} and Phyoo Kyaw Myint^{2,3,5}, Pre-Stroke Modified Rankin Scale: Evaluation of Validity, Prognostic Accuracy, and Association with Treatment, *Front Neurol.* 2017; 8: 275.