

# Chiropractic Cervical Manipulation and Arterial Dissection: Epidemiology, Mechanisms, And Forensic Implications

STEVEN B. ROSS, D.C., F.A.S.B.E., D.A.A.P.M.

*Chiropractic Physician, Independent Medical Examiner, Forensic Spine Biomechanics Expert*

**Abstract-** *Cervical spinal manipulation (CSM) is widely used to treat neck pain and headache but remains controversial because of reported associations with vertebral and carotid artery dissection and stroke. Evidence includes case reports and series suggesting possible causal links, in contrast to large epidemiologic studies that generally show an extremely low absolute risk and difficulty distinguishing causation from care-seeking for prodromal dissection symptoms (Cassidy et al., 2008; Whedon, Song, Mackenzie, et al., 2015; Xia et al., 2021). This paper reviews epidemiology, mechanisms, standards of chiropractic care, and medico-legal considerations, incorporating studies that both support and question a causal relationship between CSM and cervical artery dissection.*

**Keywords:** *Chiropractic Cervical Manipulation, Arterial Dissection, Vertebral Artery Injury, Forensic Pathology, Cerebrovascular Complications*

## I. INTRODUCTION

Spontaneous vertebral and carotid artery dissections account for a minority of ischemic strokes overall but a substantial proportion in younger adults (Engelter et al., 2007; Rubinstein et al., 2005). Neck pain and headache are common early symptoms, often prompting presentation to chiropractors or physicians (Cassidy et al., 2008; Whedon, Song, Mackenzie, et al., 2015; Turner et al., 2018). Observational data have linked recent CSM with cervical artery dissection (CeAD), yet multiple population-based analyses and systematic reviews highlight methodological limitations and potential protopathic bias (reverse causation), in which early dissection symptoms drive consultation rather than manipulation causing the dissection (Kosloff et al., 2015; Swait & Finch, 2017; Whedon, Petersen, Li, et al., 2022; Whedon, Petersen, Schoellkopf, et al., 2023).

The purpose of this paper is to synthesize current evidence on: (a) the incidence and risk of vertebrobasilar (VBA) and carotid events following CSM; (b) mechanistic plausibility; (c) the influence of prodromal symptoms and preexisting conditions; (d) chiropractic standards of care and screening; and (e) forensic assessment of causation in alleged manipulation-related stroke.

## II. EPIDEMIOLOGY AND INCIDENCE

### 2.1 Population Incidence of CeAD and Stroke

Spontaneous vertebral or carotid dissections account for approximately 2% of ischemic strokes overall but 8%–25% among young and middle-aged adults (Engelter et al., 2007; Rubinstein et al., 2005; Whedon, Song, Mackenzie, et al., 2015). Incidence estimates of VBA stroke in the general population are about 1 per 100,000 person-years (Kosloff et al., 2015; Whedon, Song, Mackenzie, et al., 2015).

### 2.2 Risk of Stroke After Chiropractic Care

Large case-control and cohort analyses have examined stroke risk after chiropractic visits. Cassidy et al. (2008) reported similar associations between recent chiropractic or primary care visits and VBA stroke, interpreting these findings as consistent with patients seeking care for prodromal dissection symptoms rather than a specific chiropractic effect. Kosloff et al. (2015) replicated Cassidy's design in U.S. commercial and Medicare Advantage populations (1,829 VBA strokes) and found no significant association between chiropractic visits and VBA stroke across any age group; primary care visits were more consistently associated with stroke, again supporting protopathic bias.

Among elderly Medicare beneficiaries (66–99 years) with neck pain, Whedon, Song, Mackenzie, et al. (2015) found that VBA stroke incidence was extremely low. The hazard of any stroke after chiropractic visits differed only slightly from that after primary care consultations, and the difference was likely not clinically significant. A subsequent Medicare claims analysis of older adults (65+ years) found that, across several time windows (7–30 days), the odds of CSM versus medical evaluation did not differ significantly between vertebral or carotid dissection cases and multiple control groups, concluding that CSM did not increase CeAD risk in this age group (Whedon, Petersen, Li, et al., 2022).

Recent commercial insurance case–control and case–crossover studies that included both vertebral artery dissection (VAD) and carotid artery dissection (CAD) also found very low absolute risk (Whedon, Petersen, Schoellkopf, et al., 2023). Prior CSM was more common among VAD patients than among stroke controls in one comparison, but primary medical evaluation was more frequent than CSM in most analytic frameworks; results were interpreted as consistent with care seeking for neck pain or headache rather than clear causation (Whedon, Petersen, Schoellkopf, et al., 2023).

Scoping and systematic reviews summarizing epidemiologic studies report incidence estimates for serious adverse events after spinal manipulation ranging from roughly 1 per 2 million manipulations

to 13 per 10,000 patients, with substantial uncertainty due to methodological limitations (Ernst, 2007; Swait & Finch, 2017; Kranenburg et al., 2017). Case–control and case–crossover studies in patients under 45 years often show an association between chiropractic visits or spinal manipulation and cervical arterial stroke, but similar associations are observed with primary care visits, and causal interpretation remains unresolved (Rubinstein et al., 2005; Swait & Finch, 2017; Kranenburg et al., 2017).

### 2.3 Case Reports and Series

Multiple case reports document temporal proximity between CSM and vertebral or carotid artery dissections, including catastrophic outcomes (Chen et al., 2022; Turner et al., 2018; Xia et al., 2021; Iwamoto et al., 2024; Ramos et al., 2021). A series of 13 patients with craniocervical dissections after chiropractic manipulation showed dissections of both the vertebral and carotid arteries, with 31% left permanently disabled or deceased (Albuquerque et al., 2011). Self-manipulation has also been associated with fatal vertebral artery dissection (Fink et al., 2024).

Case-based literature demonstrates biological plausibility and potential severity but cannot reliably estimate risk or establish causation due to lack of controls, incomplete information on prodromal symptoms, and potential publication bias (Ernst, 2007; Swait & Finch, 2017; Kranenburg et al., 2017).

Table 1: Various Study Types and Findings

Study type	General finding on CSM–stroke link	Citations
Large case–control/claims	No increased VBA/CeAD risk vs. medical visits; strong role of prodromals	Cassidy et al., 2008; Kosloff et al., 2015; Whedon, Song, Mackenzie, et al., 2015; Whedon, Petersen, Li, et al., 2022; Whedon, Petersen, Schoellkopf, et al., 2023
Scoping/systematic reviews	Serious events very rare; causality uncertain	Rubinstein et al., 2005; Swait & Finch, 2017; Kranenburg et al., 2017
Case reports/series	Temporal association; often severe outcomes; cannot quantify risk	Turner et al., 2018; Chen et al., 2022; Engelter et al., 2007; Xia et al., 2021; Iwamoto et al., 2024; Ramos et al., 2021; Fink et al., 2024; Albuquerque et al., 2011

## III. MECHANISTIC CONSIDERATIONS

### 3.1 Biomechanical Plausibility

Vertebral and carotid artery dissections result from intimal tears, intramural hematoma, and luminal compromise (Brown, 2024; Engelter et al., 2007).

High-velocity, low-amplitude (HVLA) cervical thrusts have been hypothesized to overstretch the vertebral artery, particularly at the V3 segment, which traverses the C1–C2 region and is relatively fixed and tortuous (Albuquerque et al., 2011).

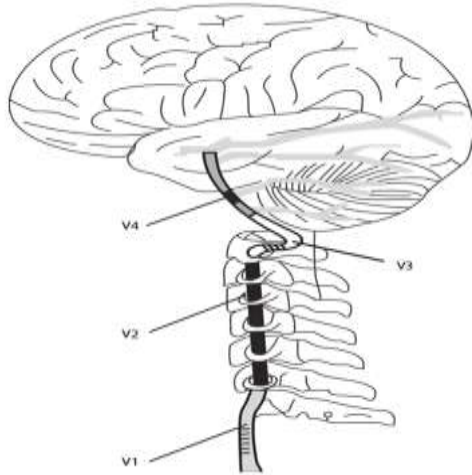


Figure 1: The vertebral artery and its four segments (V1, V2, V3, V4)

However, *in vitro* and *in vivo* biomechanical studies report that vertebral artery elongation and torque during clinically applied HVLA maneuvers remain well below experimentally determined failure thresholds (Swait & Finch, 2017; Whedon, Petersen, Li, et al., 2022; Kranenburg et al., 2017; Church et al., 2019; Puentedura et al., 2016). In cadaveric models, vertebral arteries typically fail at elongations of 18%–22% and high torques, whereas properly delivered HVLA adjustments produce average elongations below roughly 6% and substantially lower torques (Swait & Finch, 2017). These findings suggest a substantial safety margin in healthy vessels, although they may not fully account for pathological or structurally vulnerable arteries (Church et al., 2019; Puentedura et al., 2016).

### 3.2 Preexisting Pathology and Prodromal Symptoms

Neck pain and headache are common early signs of vertebral or carotid dissection and may precede stroke by days to weeks (Engelter et al., 2007; Turner et al., 2018; Chen et al., 2022). Observational studies indicate that:

- Patients with CeAD often report recent minor trauma or neck movements (including sports, coughing, and, in some reports, manipulation), yet

such exposures are common in the general population (Engelter et al., 2007; Rubinstein et al., 2005; Puentedura et al., 2016).

- Case-control and scoping reviews indicate that associations between CSM and CeAD are mirrored by similar associations with primary care visits, supporting the interpretation that pain from evolving dissection prompts health care contact (Cassidy et al., 2008; Swait & Finch, 2017; Whedon, Petersen, Li, et al., 2022; Whedon, Petersen, Schoellkopf, et al., 2023).

Some reviews and case-based analyses argue that “trivial trauma,” such as CSM, may act as a trigger in susceptible individuals, especially younger patients without conventional vascular risk factors, but acknowledge that causality cannot be established with current study designs (Rubinstein et al., 2005; Swait & Finch, 2017; Kranenburg et al., 2017; Puentedura et al., 2016; Albuquerque et al., 2011).

### 3.3 Anatomic and Clinical Risk Modifiers

Risk is influenced by factors such as connective tissue disorders, arterial hypoplasia or looping, and conditions like ankylosing spondylitis that predispose to bony and vascular injury (Albuquerque et al., 2011; Ramos et al., 2021). Case reports describe severe neurologic injury when underlying pathology (e.g., undiagnosed ankylosing spondylitis) is present, sometimes in contexts where the operator’s training or adherence to standards of chiropractic care is uncertain (Ramos et al., 2021; Ganesh & Galetta, 2022; Cupler et al., 2022).

## IV. CHIROPRACTIC STANDARDS OF CARE, SCREENING, AND ADVERSE EVENT REPORTING

### 4.1 Standards of Assessment and Informed Consent

Chiropractic standards of care typically include:

- Comprehensive history and examination to identify red flags, including recent severe or unusual headache, neck trauma, focal neurologic symptoms, or vascular risk factors (Swait & Finch, 2017; Kranenburg et al., 2017).
- Consider alternative diagnoses, including CeAD, particularly in younger patients

presenting with sudden neck pain or headache (Swait & Finch, 2017; Whedon, Song, Mackenzie, et al., 2015; Rubinstein et al., 2005).

- Discussion of the potential risks and benefits of cervical manipulation as part of informed consent, acknowledging that serious events are rare but have been reported (Swait & Finch, 2017; Kranenburg et al., 2017).

Reviews highlight that premanipulative positional tests for vertebrobasilar insufficiency are unreliable predictors of dissection risk and emphasize the importance of clinical reasoning and vascular risk assessment (e.g., blood pressure, signs suggestive of ongoing stroke; Swait & Finch, 2017; Kranenburg et al., 2017).

#### 4.2 Adverse Event Incidence and Profiles

A scoping review of 250 articles found benign adverse events (transient soreness, increased pain) to be common, whereas serious events, including cervical arterial strokes, were rare and difficult to quantify precisely (Swait & Finch, 2017). A systematic review of adverse events after cervical manipulation and mobilization identified 227 cases; cervical artery dissection occurred in 57%, and nearly half of the serious events presented immediately. However, patient characteristics were poorly reported, and no clear high-risk profile could be defined (Kranenburg et al., 2017).

A large, multi-clinic retrospective analysis of more than 960,000 spinal manipulation sessions reported only two severe adverse events (rib fractures) and no cases of stroke or cauda equina syndrome, supporting the rarity of serious complications in routine practice (Chu et al., 2023). Malpractice and protective association data similarly suggest extremely low per-visit rates of reported neurologic injury, though underreporting cannot be ruled out (Turner et al., 2018; Albuquerque et al., 2011).

#### 4.3 Regulation and Practitioner Qualifications

Some adverse event reports involve providers whose chiropractic credentials are uncertain or who practice outside regulated systems, raising concerns about generalizing risk estimates to trained, licensed

chiropractors (Ramos et al., 2021; Ganesh & Galetta, 2022; Cupler et al., 2022). Clarifying provider training and regulation is important for interpreting case reports and for forensic attribution (Ganesh & Galetta, 2022; Cupler et al., 2022).

## V. EVIDENCE FOR AND AGAINST A CAUSAL RELATIONSHIP

### 5.1 Evidence Suggesting Possible Causation

Evidence suggesting causation includes:

- Temporal proximity between CSM and dissection or stroke is reported in numerous case reports, with symptoms occasionally beginning during or immediately after manipulation (Turner et al., 2018; Chen et al., 2022; Engelter et al., 2007; Xia et al., 2021; Iwamoto et al., 2024; Ramos et al., 2021; Fink et al., 2024).
- Case series documenting arterial injuries involving the vertebral and carotid segments after chiropractic manipulation, with a minority of patients experiencing death or permanent disability (Albuquerque et al., 2011).
- Case-based reviews that interpret specific presentations as likely causal events, while acknowledging the lack of pre-event imaging (Turner et al., 2018; Brown, 2024).

### 5.2 Evidence Questioning Causation

In contrast, multiple lines of evidence call into question a direct causal relationship:

- Large population-based case-control and cohort studies (in Canada, among U.S. commercial insurers, and in Medicare and Medicare Advantage) show no excess risk of VBA stroke or CeAD after chiropractic care compared with primary medical care, particularly when accounting for timing and prodromal symptoms (Cassidy et al., 2008; Whedon, Song, Mackenzie, et al., 2015; Kosloff et al., 2015; Whedon, Petersen, Li, et al., 2022; Whedon, Petersen, Schoellkopf, et al., 2023).
- Stronger associations between primary care visits and CeAD or VBA stroke within similar time windows, consistent with symptomatic

patients seeking care from both provider types (Cassidy et al., 2008; Kosloff et al., 2015; Whedon, Petersen, Li, et al., 2022; Whedon, Petersen, Schoellkopf, et al., 2023).

- Methodological critiques and reanalysis of earlier reviews that overstated causality due to selection and reporting bias (Rubinstein et al., 2005; Swait & Finch, 2017; Whedon, Song, Mackenzie, et al., 2015).
- Biomechanical data indicate that forces during skilled HVLA manipulation are below the thresholds required to injure normal arteries, making routine mechanical rupture unlikely in the absence of preexisting vulnerability (Swait & Finch, 2017; Whedon, Petersen, Li, et al., 2022; Kranenburg et al., 2017; Church et al., 2019; Puentedura et al., 2016).

### 5.3 Integrated Interpretation

Taken together, current evidence supports several points of cautious consensus.

- The absolute risk of CeAD or stroke temporally associated with CSM is very low

(Cassidy et al., 2008; Whedon, Song, Mackenzie, et al., 2015; Swait & Finch, 2017; Kosloff et al., 2015; Whedon, Petersen, Li, et al., 2022; Whedon, Petersen, Schoellkopf, et al., 2023; Ernst, 2007; Chu et al., 2023).

- A consistent association exists between recent neck treatment (by chiropractors or physicians) and CeAD, but study design and the presence of prodromal symptoms make causality difficult to establish (Rubinstein et al., 2005; Swait & Finch, 2017; Kranenburg et al., 2017; Whedon, Petersen, Li, et al., 2022; Whedon, Petersen, Schoellkopf, et al., 2023; Engelter et al., 2007).
- In susceptible individuals with underlying vascular or connective tissue pathology, or in the presence of an evolving dissection, neck manipulation might conceivably contribute to clinical deterioration, although direct evidence is limited to case reports (Turner et al., 2018; Brown, 2024; Kranenburg et al., 2017; Albuquerque et al., 2011; Ramos et al., 2021).

Table 2 : Key Claims & Evidence

Claim	Evidence strength	Reasoning	Papers
Serious stroke/CeAD after CSM is extremely rare	Strong (8/10)	Multiple large datasets, low event counts, convergent reviews	Cassidy et al., 2008; Whedon, Song, Mackenzie, et al., 2015; Kosloff et al., 2015; Whedon, Petersen, Li, et al., 2022; Whedon, Petersen, Schoellkopf, et al., 2023; Swait & Finch, 2017; Ernst, 2007; Chu et al., 2023
Association between CSM and CeAD largely protopathic	Moderate (7/10)	Similar or greater risk with primary care visits; prodromals common	Cassidy et al., 2008; Rubinstein et al., 2005; Swait & Finch, 2017; Kranenburg et al., 2017; Whedon, Petersen, Li, et al., 2022; Whedon, Petersen, Schoellkopf, et al., 2023; Engelter et al., 2007
CSM can be temporally associated with severe outcomes	Moderate (6/10)	Repeated case reports and series, no controlled proof of causation	Turner et al., 2018; Chen et al., 2022; Engelter et al., 2007; Xia et al., 2021; Iwamoto et al., 2024; Ramos et al., 2021; Fink et al., 2024; Albuquerque et al., 2011
Biomechanical forces of skilled HVLA below failure	Moderate (6/10)	Cadaver and modeling studies; diseased vessels are uncertain	Swait & Finch, 2017; Whedon, Petersen, Li, et al., 2022; Kranenburg et al., 2017; Church et al., 2019; Puentedura et al., 2016

## VI. FORENSIC AND MEDICOLEGAL CONSIDERATIONS

In medico-legal contexts, experts must distinguish temporal association from causation “within a reasonable degree of medical probability.” Methodologically, this requires:

- Careful reconstruction of symptom chronology, including neck pain, headache, neurologic deficits, and the timing of CSM (Brown, 2024; Engelter et al., 2007; Cassidy et al., 2008; Chen et al., 2022; Xia et al., 2021; Iwamoto et al., 2024; Ramos et al., 2021).
- Detailed imaging review (CTA/MRA) to identify dissection features (intimal flap, intramural hematoma, double lumen) and assess anatomical segment involvement (Brown, 2024; Chen et al., 2022; Albuquerque et al., 2011).
- Consideration of alternative and co-acting causes (underlying disease, other trauma, self-manipulation) and adherence to chiropractic standards for history, examination, referral, and consent (Turner et al., 2018; Albuquerque et al., 2011; Fink et al., 2024; Ramos et al., 2021; Ganesh & Galetta, 2022; Cupler et al., 2022).

Some forensic analyses conclude that, in the absence of compelling evidence of mechanical causation, VAD may be best considered an already present condition at the time of CSM, with liability focused on failure to recognize and refer rather than on the manipulation itself (Brown, 2024; Engelter et al., 2007; Whedon, Petersen, Schoellkopf, et al., 2023; Albuquerque et al., 2011).

## VII. CONCLUSION

The relationship between cervical spinal manipulation and cervical artery dissection is complex. Serious vascular events temporally associated with CSM are well documented but rare. Case-based literature illustrates their potential severity, whereas large epidemiologic studies generally fail to show an increased population-level risk compared with primary medical care. Biomechanical data argue against routine mechanical

injury to normal arteries, while clinical data highlight the central role of prodromal neck pain and headache in evolving dissections.

An unbiased review of current evidence supports continued emphasis on meticulous clinical assessment and screening, frank discussion of rare but serious risks, prompt recognition and referral of suspected CeAD, and improved adverse event reporting and research methods. Forensic assessments should integrate epidemiologic, biomechanical, and case-specific clinical data while avoiding both unwarranted exoneration and overattribution of causation to chiropractic manipulation.

## REFERENCES

- [1]. Albuquerque, F. C., Hu, Y. C., Dashti, S. R., et al. (2011). Craniocervical arterial dissections as sequelae of chiropractic manipulation: Patterns of injury and management. *Journal of Neurosurgery*, 115(6), 1197–1205.
- [2]. Brown, S. (2024). Causal analysis of vertebral artery dissection and fatal stroke following chiropractic cervical spine manipulation. *Forensic Science International Reports*.
- [3]. Cassidy, J. D., Boyle, E., Côté, P., et al. (2008). Risk of vertebrobasilar stroke and chiropractic care: Results of a population-based case-control and case-crossover study. *Spine*, 33(4S), S176–S183.
- [4]. Chen, Y., Mofatteh, M., Nguyen, T. N., et al. (2022). Carotid artery dissection and ischemic stroke following cervical chiropractic manipulation: Two case reports. *Vascular and Endovascular Surgery*, 56(4), 404–409.
- [5]. Chu, E. C. P., Trager, R. J., Lee, L. Y., & Niazi, I. (2023). A retrospective analysis of the incidence of severe adverse events among recipients of chiropractic spinal manipulative therapy. *Scientific Reports*, 13, 9785.
- [6]. Church, E. W., et al. (2019). [Referenced in broader CeAD risk discussions; biomechanical and clinical commentary].
- [7]. Cupler, Z. A., Trager, R. J., & Daniels, C. J. (2022). Letter: Cervical spinal manipulative

- therapy unlikely cause of spontaneous internal carotid artery dissection. *Vascular and Endovascular Surgery*, 56(4), 410–412.
- [8]. Engelter, S. T., et al. (2007). Cervical artery dissection and history of minor cervical trauma. *Stroke*, 38(3), 803–808.
- [9]. Ernst, E. (2007). Adverse effects of spinal manipulation: A systematic review. *Journal of the Royal Society of Medicine*, 100(7), 330–338.
- [10]. Fink, C., Bryce, C. H., & Knight, L. D. (2024). Self chiropractic cervical spinal manipulation resulting in fatal vertebral artery dissection. *American Journal of Forensic Medicine and Pathology*.
- [11]. Ganesh, A., & Galetta, S. (2022). Editors' note on spinal cord injury, vertebral artery dissection, and cerebellar strokes after chiropractic manipulation. *Neurology*, 99(8), 357–359.
- [12]. Iwamoto, S., Hsu, M., Ta, A. P., et al. (2024). Twists and turns: Bilateral vertebral artery dissection after chiropractic manipulation and roller coaster riding. *Cureus*, 16(1), e000000.
- [13]. Kosloff, T. M., Elton, D., Tao, J., & Bannister, W. (2015). Chiropractic care and the risk of vertebrobasilar stroke: Results of a case-control study in U.S. commercial and Medicare Advantage populations. *Chiropractic & Manual Therapies*, 23, 19.
- [14]. Kranenburg, H. A., Schmitt, M. A., Puentedura, E. J., et al. (2017). Adverse events associated with cervical spine manipulation or mobilization and patient characteristics: A systematic review. *Musculoskeletal Science and Practice*, 28, 32–38.
- [15]. Puentedura, E. J., O'Grady, W. H., et al. (2016). Safety of thrust joint manipulation in the cervical spine: A systematic review. *Manual Therapy*, 21, 189–196.
- [16]. Ramos, G., Martins, R. R., de Souza, J. C. C., et al. (2021). Spinal cord injury, vertebral artery dissection, and cerebellar strokes after chiropractic manipulation. *Neurology*, 96(11), e1512–e1515.
- [17]. Rubinstein, S. M., Peerdeman, S. M., van Tulder, M. W., et al. (2005). A systematic review of the risk factors for cervical artery dissection. *Stroke*, 36(7), 1575–1580.
- [18]. Swait, G., & Finch, R. (2017). What are the risks of manual treatment of the spine? A scoping review for clinicians. *Chiropractic & Manual Therapies*, 25, 37.
- [19]. Swait, G., & Finch, R. (2017). Benign and serious adverse events in manual therapy: A scoping review. *Chiropractic & Manual Therapies*, 25, 35.
- [20]. Turner, R., Lucke Wold, B., Boo, S., et al. (2018). The potential dangers of neck manipulation and risk for dissection and devastating stroke: An illustrative case and review of the literature. *Biomedical Research and Reviews*.
- [21]. Whedon, J. M., Petersen, C., Li, Z., et al. (2022). Association between cervical artery dissection and spinal manipulative therapy: A Medicare claims analysis. *BMC Geriatrics*, 22, 27.
- [22]. Whedon, J. M., Petersen, C., Schoellkopf, W. J., et al. (2022). Cervical artery dissection and spinal manipulative therapy among older Medicare beneficiaries. *BMC Geriatrics*, 22, 106.
- [23]. Whedon, J. M., Petersen, C., Schoellkopf, W. J., et al. (2023). The association between cervical artery dissection and spinal manipulation among U.S. adults. *European Spine Journal*, 32(5), 1101–1112.
- [24]. Whedon, J. M., Song, Y., Mackenzie, T. A., et al. (2015). Risk of stroke after chiropractic spinal manipulation in Medicare B beneficiaries aged 66–99 years with neck pain. *Journal of Manipulative and Physiological Therapeutics*, 38(2), 93–101.
- [25]. Xia, C., Pfaff, L., Kaur, N., et al. (2021). Chiropractor manipulation leading to bilateral vertebral artery dissection and acute ischemic stroke. *Stroke: Vascular and Interventional Neurology*, 1(4), e000141.